



animalendocrineclinic

Dr. Mark E. Peterson

*Where science and compassion cure
endocrinology | hypurrcat | nuclear imaging*



What Should You Expect From The Facility Providing **Radioiodine (I-131) Therapy** For Your Hyperthyroid Cat?

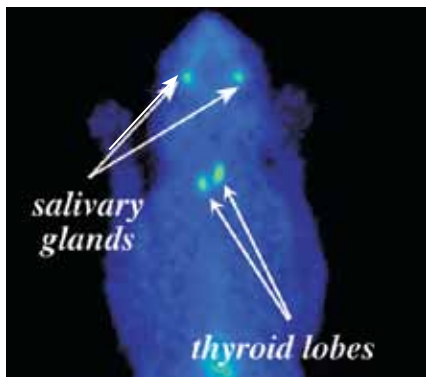
In a word, confidence.

Confidence in the diagnosis:

Hyperthyroidism is caused by one or more small, usually benign, tumors in the thyroid gland.¹⁻³ These tumors function autonomously to produce the high circulating thyroid hormone concentrations responsible for hyperthyroidism. Diagnosing hyperthyroidism is usually straightforward. Generally, documenting a high serum T₄ (thyroxine) concentration in a cat with compatible historical and physical examination findings is sufficient to confidently diagnose hyperthyroidism.³⁻⁵

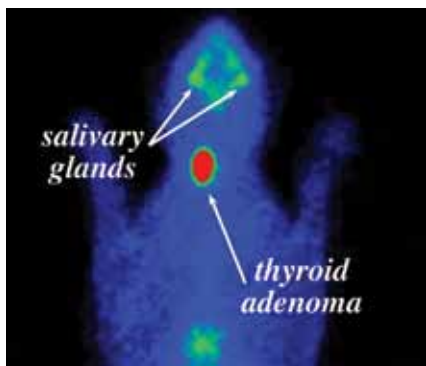
Unfortunately, not all cats with hyperthyroidism will have a high T₄ concentration. Sometimes, cats with early or mild hyperthyroidism have normal or only slightly high serum T₄ concentrations.⁶ As a result, other tests have been designed to aid in the diagnosis of hyperthyroidism in cats with early or mild disease.^{4,6-8} Currently, the non-protein bound or “free” T₄ is considered the most sensitive laboratory test for diagnosing mild hyperthyroidism in cats.⁴ Unfortunately, this test is not perfect either. Between 6-12% of all cats with nonthyroidal illness will have a falsely-high free T₄ value.^{4,9} However, because these cats are not hyperthyroid, treatment will be of no benefit and will likely result in hypothyroidism.

A diagnostic imaging procedure called thyroid scintigraphy or thyroid scanning has long been considered the “gold standard” for diagnosing feline hyperthyroidism.¹⁰⁻¹² After administering a short-acting radionuclide that concentrates in thyroid tissue, thyroid imaging directly visualizes the normal thyroid gland, as well as the small tumor(s) responsible for hyperthyroidism in cats. Because this procedure utilizes the physiology of the thyroid gland to create an image, thyroid imaging is so sensitive that it can actually demonstrate the presence of hyperfunctional thyroid tumors long before they become clinically significant or result in laboratory value abnormalities.¹⁰⁻¹² Unfortunately, because of the costly nuclear medicine equipment and the special licensing required, most radioiodine treatment facilities elect not to offer thyroid imaging for their hyperthyroid cat patients.



Thyroid image of a cat with normal thyroid function. Note the similar uptake of radionuclide in the two normal thyroid lobes and the salivary glands.

At **Hypurrcat**, we have the nuclear medicine imaging equipment and special licensing required to perform thyroid scintigraphy. This allows us to readily perform thyroid imaging in any cat that needs it to accurately confirm the diagnosis of hyperthyroidism. This is especially helpful in cats with borderline high T₄ concentrations but no palpable thyroid nodule.



Thyroid image of a hyperthyroid cat with a unilateral thyroid adenoma. Notice the increased uptake of the radionuclide in the thyroid as compared to the salivary tissue.

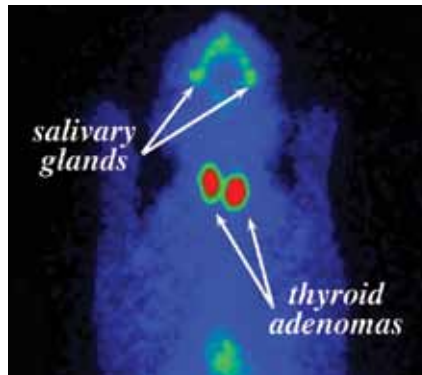
Confidence in the I-131 dose determination:

Numerous methods for determining the radioiodine dose for cats with hyperthyroidism have been described in veterinary literature.¹³⁻¹⁹ These methods are quite variable but include two basic categories:

- 1) individualized or “patient-specific” dose determination; and
- 2) fixed or “one size fits all” dosing.

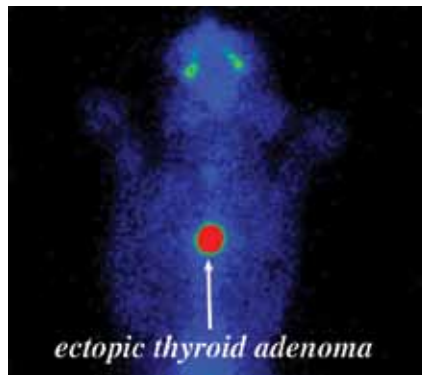
The individualized dosing methods attempt to maximize the success of the therapy by considering a number of patient-specific variables. These variables include the size of the thyroid tumor, the degree of hyperthyroidism, and several specific physiologic parameters, such as biologic half-life and iodine uptake.¹⁹⁻²²

The fixed dose approach, on the other hand, assumes that most hyperthyroid cats can be successfully treated by administering the same “fixed” dose to all cats, no matter how large their thyroid tumor or their degree of hyperthyroidism.¹⁴ However, to attain a reasonable success rate with this method, a large number of cats are either over- or under-dosed with I-131. Therefore, both the incidence of long-term hypothyroidism and persistent hyperthyroidism are higher with this dosing method.



Thyroid image of a hyperthyroid cat with bilateral thyroid adenomas. Notice the increased uptake of the radionuclide in the thyroid tissue bilaterally.

At **Hypurrcat**, we personally tailor the I-131 dose administered to each hyperthyroid cat. This individualized dosing method not only results in a >98% cure rate, but also greatly decreases the incidence of permanent hypothyroidism after therapy.



Thyroid image of a hyperthyroid cat with a single ectopic (intrathoracic) thyroid adenoma. Note the location of the adenoma within the thorax. This cat had NO palpable thyroid enlargement.

Dr. Peterson has proven that he can accurately estimate tumor size by physical palpation of the thyroid gland.¹⁹ However, about a third of hyperthyroid cats have thyroid tumors located within the thoracic cavity that cannot be palpated.²³

Most hyperthyroid cats without palpable cervical nodules have thyroid tumors (adenoma or carcinomas) that have become extremely large. Because of the chronic effects of gravity on the progressively enlarging thyroid mass, these tumors migrate into the thoracic cavity. Other cats develop hyperthyroidism secondary to adenomas of ectopic, intrathoracic, thyroid tissue. Both of these situations render these thyroid tumors beyond the reach of palpation. Finally, in cats with a thyroid carcinoma, extension or metastasis to the thoracic cavity is common, so physical palpation alone will grossly underestimate the full extent of these malignant tumors.²³⁻²⁵

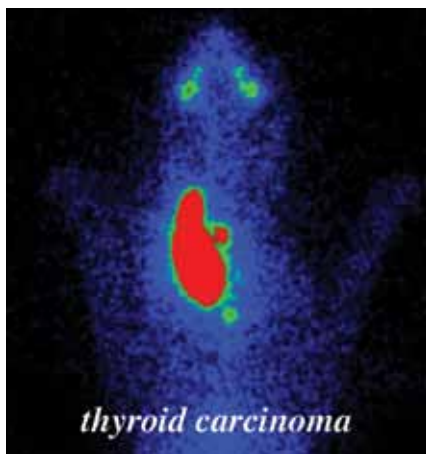
At **Hypurrcat**, we recommend thyroid scintigraphy for all cats with suspected intrathoracic thyroid tumors (e.g., when the thyroid tumor is not easily palpable). We also perform thyroid imaging on all cats in which thyroid carcinoma is known or suspected. This allows us to calculate the proper dose needed to adequately treat cats with large thyroid adenomas or carcinomas. Most radioiodine facilities are not licensed to treat cats with thyroid carcinoma with the large doses needed to cure these cats (i.e., up to 10 times the I-131 dose that typical cats with thyroid adenoma need). However, Dr. Peterson has successfully treated many cats with thyroid carcinoma over the last 30 years.

Confidence in the care the facility and staff provide for your cat during their hospitalization following the I-131 treatment:

Cats undergoing radioiodine therapy usually do not require intensive medical care. Although there are no reported side effects associated with the radioiodine treatment itself, the average age of the cats with this disease is 13 years.^{1,3}

The effects of the chronic thyroid hormone excess on other organ systems, especially the cardiovascular system, can be significant. Major concurrent conditions necessitating ongoing therapy are common in these cats. Common concurrent conditions include, but are not limited to, renal insufficiency, inflammatory bowel disease, congestive heart failure, and diabetes mellitus.

At **Hypurrcat**, Dr. Peterson directly evaluates, treats, and supervises all cats receiving radioiodine therapy during their hospital stay. Dr. Peterson is both a pioneer and a recognized expert in the field of feline hyperthyroidism; he was the first to describe the disease in 1979²⁶ and was the first veterinarian to use radioiodine to treat cats with hyperthyroidism in 1980.^{27,28} Dr. Peterson has authored numerous scientific articles on the use of radioiodine to treat cats with hyperthyroidism,²⁹ including the largest case series on the subject in the veterinary literature.¹⁹ He has personally treated over 10,000 cats with hyperthyroidism during his 30-plus year career.



Thyroid image of a hyperthyroid cat with functional thyroid carcinoma. Notice the extension of the disease beyond the limits of the normal thyroid capsule. This represents regional metastasis characteristic of malignant disease.

Confidence that the facility understands that your cat is a member of the family:

The bond shared between pet owners and their cat can be unlike any other. Pet owners may worry immensely about their cats when they are hospitalized for radioiodine treatment.

At **Hypurrcat**, we understand the special role that your cat plays in the owner's family. Our entire Hypurrcat team is committed to providing personal attention to the unique concerns of each cat and cat owner. The cat's caretaker feeds, monitors, and brushes your cat throughout the day, then calls or emails the owner with a daily update.

Confidence that the facility provides your cat with "environmental enrichment" during their hospitalization:

Cats, especially those hospitalized for more than a day or two, need both stimulation and recreation to maintain their mental health. This is often referred to as "environmental enrichment" or "environmental enhancement." Examples include an environment with perches, hiding boxes, beds, and toys, as well as "safe" places to sleep, eat, and use the litter box. Daily positive interaction with their human caretakers also benefits hospitalized cats. Spending a few minutes each day petting, brushing, and playing with the cats, as well as speaking to them in a soft, calming voice, provides comfort to them.

At **Hypurrcat**, we know that cats are much happier during their hospitalization when boarded in large condos and provided with live entertainment. Each of our cat condos has a separate bathroom (with litter box), a perch that allows the cat to get above the action, a hiding box, as well as their own bed and toys. Our Hypurrcat treatment facilities are strictly "For Cats Only!" We have no dogs barking in the background; the cats hear only soft music played throughout the day. To help keep cats entertained during their stay at Hypurrcat, we offer a wide selection of cat videos that are shown on a widescreen TV within the treatment room. Furthermore, we feature live entertainment.

At our NYC **Hypurrcat** facility, the cats enjoy 40 x 27 x 25 inch condos and a great window view of the back courtyard, where we have multiple bird feeders set up. The cats can observe the birds and squirrels feeding just a few yards away.

At our Westchester **Hypurrcat** facility, we are often able to link two of these condos together in order to give each cat his or her own private double-sized condo. The cats can also view two gerbil habitats in front of their condos, where the gerbils scurry through habitrails and run on exercise wheels.

Confidence that the facility allows you to observe your cat during their hospitalization:

Almost all owners would like to visit during their cat's stay with us, but this is not allowed because of New York State and City regulations. That's why we offer owners and veterinarians the ability to monitor their cats live over the Internet (even on a smartphone).

Both of our **Hypurrcat** facilities have private cameras installed in each of the cat condos. The web cams allow both the owner and referring veterinarian to check in on their cat, even though they cannot visit. Furthermore, the web cams allow Dr. Peterson to frequently monitor the cats, even when he is not in the office.


Confidence that the facility and staff remain available for consultation even long after the treatment:

At **Hypurrcat**, part of our mission is to ensure that our patients always receive the best possible long-term medical care. We give detailed discharge instructions to each cat owner and send a follow-up letter with our recommendations to their referring veterinarian. Furthermore, Dr. Peterson is available for consultation both during the cat's hospitalization as well as anytime after the cat has been discharged.

Confidence that the facility will schedule and perform your cat's treatment promptly:

At **Hypurrcat**, we understand that you want your cat treated as soon as possible - and we agree with you. Not only do we perform treatments every week, but we also have two fully equipped facilities. Between frequent treatments and ample space, we make sure that your cat receives the prompt, effective, and personalized treatment that he or she deserves.

1. **Peterson ME**, Kintzer PP, Cavanagh PG, et al. Feline hyperthyroidism: pretreatment clinical and laboratory evaluation of 131 cases. *J Am Vet Med Assoc* 1983; 183:103-110.
2. Gerber H, Peter H, Ferguson DC, **Peterson ME**, et al. Etiopathology of feline toxic nodular goiter. *Vet Clin North Am Small Anim Pract* 1994; 24:541-565.
3. Mooney CT, **Peterson ME**: Feline hyperthyroidism, In: Mooney C.T., Peterson M.E. (eds), *Manual of Endocrinology (Third Ed)*, Quedgeley, Gloucester, British Small Animal Veterinary Association, pp. 95-111, 2004.
4. **Peterson ME**, Melian C, Nichols R. Measurement of serum concentrations of free thyroxine, total thyroxine, and total triiodothyronine in cats with hyperthyroidism and cats with nonthyroidal disease. *J Am Vet Med Assoc* 2001; 218:529-36.
5. **Peterson ME**. Diagnostic tests for hyperthyroidism in cats. *Clin Tech Small Anim Pract* 2006; 21:2-9.
6. Graves TK, **Peterson ME**. Occult hyperthyroidism in cats In: Kirk RW, Bonagura JD, eds. *Current Veterinary Therapy XI*. Philadelphia: W.B. Saunders, 1992; 334-337.
7. **Peterson ME**, Graves TK, Gamble DA. Triiodothyronine (T3) suppression test. An aid in the diagnosis of mild hyperthyroidism in cats. *J Vet Intern Med* 1990; 4:233-238.
8. **Peterson ME**, Broussard JD, Gamble DA. Use of the thyrotropin releasing hormone stimulation test to diagnose mild hyperthyroidism in cats. *J Vet Intern Med* 1994; 8:279-286.
9. Mooney CT, Little CJ, Macrae AW. Effect of illness not associated with the thyroid gland on serum total and free thyroxine concentrations in cats. *J Am Vet Med Assoc* 1996; 208:2004-2008.
10. **Peterson ME**, Becker DV. Radionuclide thyroid imaging in 135 cats with hyperthyroidism. *Vet Radiol* 1984; 25:23-27.
11. Kintzer PP, **Peterson ME**. Nuclear medicine of the thyroid gland. Scintigraphy and radioiodine therapy. *Vet Clin North Am Small Anim Pract* 1994; 24:587-605.
12. Broome MR. Thyroid scintigraphy in hyperthyroidism. *Clin Tech Small Anim Pract* 2006; 21:10-16.
13. Turrel JM, Feldman EC, Hays M, et al. Radioactive iodine therapy in cats with hyperthyroidism. *J Am Vet Med Assoc* 1984; 184:554-559.
14. Meric SM, Rubin SI. Serum thyroxine concentrations following fixed-dose radioactive iodine treatment in hyperthyroid cats: 62 cases (1986-1989). *J Am Vet Med Assoc* 1990; 197:621-623.
15. Mooney CT. Radioactive iodine therapy for feline hyperthyroidism: efficacy and administration routes. *J Sm Anim Pract* 1994; 35:289-294.
16. Malik R, Lamb WA, Church DB. Treatment of feline hyperthyroidism using orally administered radioiodine: a study of 40 consecutive cases. *Aust Vet J* 1993; 70:218-219.
17. Theon AP, Van Vechten MK, Feldman E. Prospective randomized comparison of intravenous versus subcutaneous administration of radioiodine for treatment of hyperthyroidism in cats. *Am J Vet Res* 1994; 55:1734-1738.
18. Forrest LJ, Baty CJ, Metcalf MR, et al. Feline hyperthyroidism: efficacy of treatment using volumetric analysis for radioiodine dose calculation. *Vet Radiol* 1994; 37:141-145.
19. **Peterson ME**, Becker DV. Radioiodine treatment of 524 cats with hyperthyroidism. *J Am Vet Med Assoc* 1995; 207:1422-1428.
20. Broome MR, Turrel JM, Hays MT. Predictive value of tracer studies for ¹³¹I treatment in hyperthyroid cats. *Am J Vet Res* 1988; 49: 193-197.
21. Hays MT, Broome MR, Turrel JM. A multicompartmental model for iodide, thyroxine, and triiodothyronine metabolism in normal and spontaneously hyperthyroid cats. *Endocrinology* 1988; 122:2444-2461.
22. Broome MR, Hays MT, Turrel JM. Peripheral metabolism of thyroid hormones and iodide in healthy and hyperthyroid cats. *Am J Vet Res* 1987; 48:1286-1289.
23. Harvey AM, Hibbert A, Barrett EL, et al. Scintigraphic findings in 120 hyperthyroid cats. *J Feline Med Surg* 2009; 11:96-106.
24. Guptill L, Scott-Moncrieff CR, Janovitz EB, et al. Response to high-dose radioactive iodine administration in cats with thyroid carcinoma that had previously undergone surgery. *J Am Vet Med Assoc* 1995; 207:1055-1058.
25. Hibbert A, Gruffydd-Jones T, Barrett EL, et al. Feline thyroid carcinoma: diagnosis and response to high-dose radioactive iodine treatment. *J Feline Med Surg* 2009; 11:116-124.
26. **Peterson ME**, Johnson JG, Andrews LK. Spontaneous hyperthyroidism in the cat *Proceedings of the American College of Veterinary Internal Medicine* 1979:p. 108.
27. **Peterson ME**, Becker DV, Hurley J. Feline hyperthyroidism: Further definition. *Proceedings of the American College of Veterinary Internal Medicine* 1980.
28. Becker DV, **Peterson ME**. Radioactive iodine treatment of feline hyperthyroidism. *Proceedings of the Annual Veterinary Medical Forum (American College of Veterinary Internal Medicine)* 1983; 1:p. 40.
29. **Peterson ME**: Radioiodine for hyperthyroidism. In: Bonagura JD, Twedt DC (eds): *Current Veterinary Therapy XIII*. Philadelphia, Saunders Elsevier 2009, pp. 180-184.



Hypurr cat™

A Treatment Center for Hyperthyroid Cats



animalendocrineclinic

Dr. Mark E. Peterson

21 West 100th Street, New York, NY 10025
Telephone. **212.362.2650** • Facsimile. **212.537.6340**

29 Haines Road, Bedford Hills, NY 10507
Telephone. **914.864.1631** • Facsimile. **914.864.1632**

animalendocrine.com | hypurrcat.com | nuclearimaginganimals.com