animalendocrineclinic

Dr. Mark E. Peterson

*Where science and compassion cure*

*endocrinology | hypurrcat | nuclear imaging*


# Nuclear Imaging for Animals

*An overview*

## What is nuclear imaging?

Nuclear imaging, also called nuclear scintigraphy or nuclear scanning, is an important branch of radiology that provides diagnostic information that cannot be obtained with more common imaging techniques, such as radiographs (x-rays), computed tomography (CT), magnetic resonance imaging (MRI), and ultrasound scans.

To perform nuclear imaging, a small dose of a radioactive tracer (a radionuclide or a radiopharmaceutical) is first administered to the patient. These radioactive doses are not dyes or toxic drugs, and they have no side effects. The amount of radiation a canine or feline patient receives for an imaging study is very low. However, in some cases, patients may need to stay at the hospital for 12 to 24 hours while they clear the radioactive tracer.

Each type of nuclear imaging procedure uses a radionuclide with a specific affinity for the tissue or organ of interest (e.g., the thyroid gland in a cat with hyperthyroidism). Therefore, the radioactive dose accumulates in the organ of the body being examined, where it gives off energy in the form of gamma rays (electromagnetic waves similar to x-rays). A gamma camera is used to detect this emitted energy, creating images that detail both the structure and function of the organs being studied.

## How does nuclear imaging differ from other imaging procedures?

In nuclear imaging, the radioactive agent is given internally (intravenously, subcutaneously, or rectally depending on procedure). Then, a gamma camera forms images from the radiation emitted by the radioactive tracer. This process is unlike a diagnostic X-ray or CT scan, where external radiation is passed through the body to form an image.

Nuclear imaging studies are also more organ and tissue specific than those in conventional radiologic imaging, which focus on a particular section of the body (e.g., thyroid, liver, kidney, or bone scan vs. chest X-ray, abdomen CT scan, and cranial MRI scan).

Finally, another major difference between scintigraphy and other imaging studies is that scintigraphy shows the physiological function of the organs or tissues being studied. Nuclear imaging assesses how organs function, whereas all other imaging methods assess anatomy, or how the organs look. Such functional imaging is the strength of nuclear imaging, as it can readily detect disease at an earlier stage than anatomic imaging procedures can.

## What are some common uses of nuclear imaging procedures?

At the Animal Endocrine Clinic's division of Nuclear Imaging for Animals, we perform five types of nuclear imaging studies or scans.

*1) Thyroid scintigraphy (Thyroid scan)*

*2) Portal scintigraphy (Portal scan; Liver scan)*

*3) Bone scintigraphy (Bone scan)*

*4) Renal scintigraphy (Renal or Kidney scan)*

*5) Determination of glomerular filtration rate (GFR) by plasma radiotracer clearance*

## Thyroid Scintigraphy

Thyroid scintigraphy provides valuable information regarding both thyroid anatomy and physiology and can play an integral role in the diagnosis, staging, and management of thyroid disease in both dogs and cats. Thyroid scintigraphy is considered the "gold standard" for diagnosing mild hyperthyroidism in cats. In addition, thyroid scanning is an invaluable tool for evaluating the stage and extent of thyroid tumors (adenomas and carcinomas) in both dogs and cats. Finally, although most veterinarians diagnose hypothyroidism in dogs with serum thyroid hormone tests, it is now clear that thyroid imaging is also the best way to confirm the diagnosis of that common disorder.

To perform thyroid imaging, a small radionuclide dose is administered subcutaneously. Twenty minutes later, the patients are laid on their abdomen (ventral view) or side (lateral view) while the gamma camera acquires the thyroid image. The scanning process itself only takes about 3 minutes and generally does not require sedation.

In normal cats and dogs, the thyroid gland appears on thyroid scans as two well-defined, focal (ovoid) areas of radionuclide accumulation in the cranial to middle cervical region. The two thyroid lobes are symmetrical in size and shape and are located side by side. Activity in the normal thyroid closely approximates activity in the salivary glands, with an expected "brightness" ratio of 1:1.

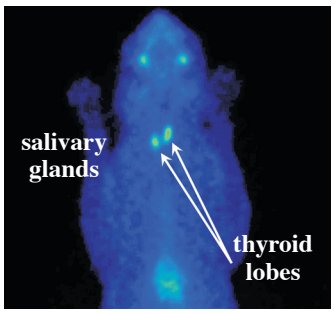


*Planar thyroid scintigraphy of a normal cat. Notice the similar uptake of the radionuclide in the normal thyroid lobes and salivary glands.*

### Hyperthyroid Cats:

Because thyroid scintigraphy directly visualizes functional thyroid tissue, thyroid imaging can diagnose hyperthyroidism before laboratory tests are consistently abnormal. Thyroid scanning can also prevent misdiagnosis of hyperthyroidism in cats with falsely high serum thyroid hormone values.

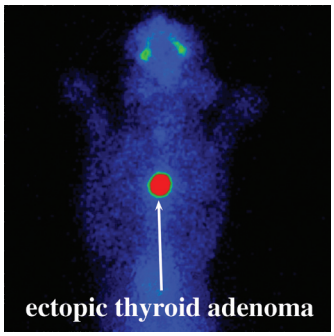


*Planar thyroid scintigraphy of a hyperthyroid cat with a single ectopic (and intrathoracic) thyroid adenoma. Notice the location of the adenoma within the thorax (chest). This cat had no palpable thyroid enlargement.*

Thyroid scintigraphy has three more uses in cats. First, it is an excellent method for evaluating the size of ectopic thyroid tissue, which can be located anywhere from base of the tongue to the heart. Second, it can locate large tumors that gravity has pulled into the thoracic cavity. Finally, thyroid scintigraphy also provides valuable information for diagnosing and evaluating cats with thyroid carcinomas.

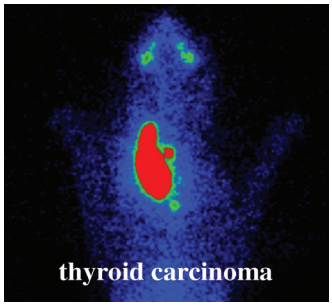


*Planar thyroid scintigraphy of a hyperthyroid cat with a functional thyroid carcinoma. Notice the extension of the disease beyond the limits of the normal thyroid capsule. This represents regional metastasis characteristic of malignant disease.*

### Dogs with Thyroid Tumors and Thyroid Cancer:

Unlike the small, benign thyroid tumors that cause hyperthyroidism in cats, most canine thyroid tumors are large, malignant, and do not cause hyperthyroidism. Scintigraphy can determine both the size of the primary tumor as well as the location of the metastases that occur in 65 to 90% of these dogs.

### Dogs with Hypothyroidism:

Quantitative thyroid imaging is a useful tool in confirming a diagnosis of hypothyroidism in dogs. Thyroid imaging typically reveals decreased or even absent radionuclide uptake in dogs with hypothyroidism (thyroid gland is not visible on the scan). In contrast, dogs that have falsely low serum thyroid hormone concentrations secondary to illness or drug therapy have a normal thyroid image. Of all of the current thyroid imaging techniques (CT, ultrasound), nuclear imaging is considered to be the best test for dogs with suspected hypothyroidism.